

Dental surgical management of the patient with hemophilia

Amana Farrkh, DDS ■ Emilia Garrison, DDS ■ James J. Closmann, DDS

The dental surgical management of a patient with a bleeding disorder can present a challenge to the dental provider. This article reviews the clinical presentation of hemophilia and describes the management of 2 patients with hemophilia who presented for dental extractions. Each patient's hematologist was consulted to determine clotting factor replacement therapy, antifibrinolytic therapy, and local measures to obtain hemostasis perioperatively. Careful coordination with the patient's hematologist in such cases is essential to ensure safe treatment.

Received: February 3, 2015

Accepted: April 22, 2015

Hemophilia is an X-linked recessive disorder caused by a deficiency in blood coagulation factors. It is the second most common coagulation disorder after von Willebrand disease.¹ Von Willebrand disease is prevalent in approximately 1% of the general population and affects both males and females with equal frequency.¹ Hemophilia A is characterized by a deficiency of factor VIII (FVIII), whereas hemophilia B is caused by a deficiency of factor IX (FIX). The incidence is estimated to be 1 in 5000 males for hemophilia A and 1 in 30,000 males for hemophilia B.² Since hemophilia is X-linked, men typically express the disease, whereas women tend to be asymptomatic carriers. It is not uncommon for dental practitioners to encounter patients with bleeding disorders in their daily practice; therefore, it is essential to be able to identify such patients and safely manage their dental treatment.

The management of patients with bleeding disorders such as hemophilia can pose a significant challenge to dental providers and requires collaboration with the patient's hematologist as well as an awareness of local hemostatic measures and techniques that cause the least amount of trauma. Routine dental procedures can cause soft tissue trauma as well as local bleeding. However, in patients with bleeding disorders, bleeding may be more prolonged and problematic. Fatal hemorrhage in hemophiliac patients has been reported following local anesthetic injections for routine dental procedures.¹ Occasionally, prolonged bleeding following dental extractions may be the first sign that a patient has an undiagnosed bleeding disorder, warranting a referral to a hematologist.¹

When treating patients with bleeding disorders such as hemophilia, the dental provider must pay special attention to treatment planning, location, and setting of the treatment, after consultation with the patient's hematologist. Preoperative consultation with the patient's medical provider is essential, as further laboratory tests may be needed before any dental treatment is rendered.³ These patients may require prophylactic therapy prior to their dental procedures, various adjustments to their treatment perioperatively, and special precautions postoperatively.

Case 1

A 10-year-old boy was referred by his orthodontist to the University of Colorado School of Dental Medicine for extraction of teeth 5, 12, 21, and 28 as well as tooth C. He had hemophilia A, for which he received treatment at the Hemophilia and Thrombosis Center at the Children's Hospital in Colorado. Additionally, the patient suffered from attention deficit hyperactivity disorder, for which he took the drug Adderall. The boy had no prior surgeries, and his medical review revealed no problems except the previously mentioned conditions. The patient had a diagnosis of mild hemophilia A with an FVIII level of approximately 18%. The patient had no known drug allergies. The patient's mother stated that he

**GENERAL DENTISTRY
SELF-INSTRUCTION**



Exercise No. 388, p. 18

Subject code: Dentistry for the Medically Compromised (754)

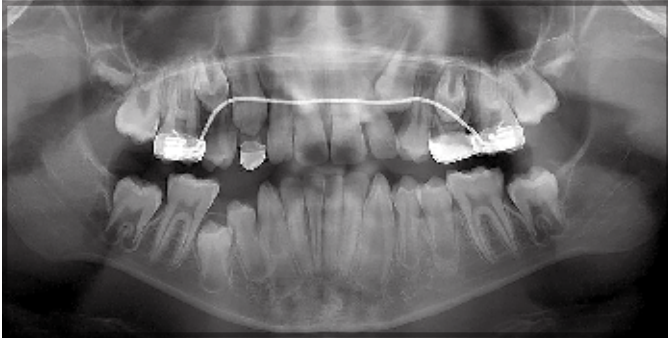


Fig 1. Case 1. Panoramic radiograph of a 10-year-old patient presenting for extraction of teeth 5, 12, 21, and 28, as well as tooth C, as requested by his orthodontist.

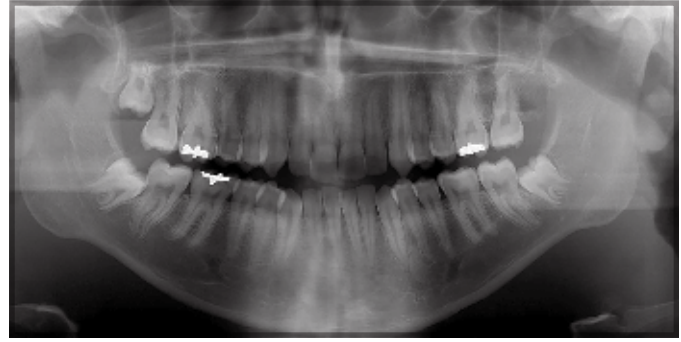


Fig 2. Case 2. Panoramic radiograph of a 17-year-old patient presenting for extraction of impacted molar teeth 1, 17, and 32.

required FVIII supplementation in response to trauma to control bleeding and that the patient had a sister who was a carrier of the hemophilia gene.

On physical examination, the patient presented as a well-developed, well-nourished boy weighing 32.9 kg. Teeth 5, 12, 21, and C were erupted, while tooth 28 was impacted under the soft tissue (Fig 1).

In coordination with the Hemophilia and Thrombosis Center at the Children's Hospital, the patient was taken to the operating room for extraction of his teeth. One hour prior to surgery, his FVIII levels were corrected to 80%-100%, equating to 40-50 U/kg of FVIII (Advate [Antihemophilic Factor {Recombinant}], Baxalta US, Inc). One 150- μ g spray of desmopressin acetate (Stimate, CSL Behring) was applied in 1 nostril 1 hour prior to the procedure. Another 150- μ g spray was given 24 hours postprocedure. Since the patient was not allowed to consume anything by mouth prior to the procedure, he also took aminocaproic acid (Amicar, Akorn, Inc) every 6 hours for 3 days starting immediately after the extractions.

The surgery was accomplished without incident. The extraction sockets were packed with gelatin foam sponges covered with topical thrombin and sutured with slowly resorbing sutures. Hemostasis was noted to be adequate, and the patient was discharged after recovery from anesthesia. The boy was advised to avoid chewing hard foods and sucking on a straw for 3 days postoperatively to avoid dislodging the fibrin clot.

Nine days postoperatively, the patient returned to the Hemophilia and Thrombosis Center with a chief complaint of bleeding after eating solid foods. The patient was infused with FVIII to 100% activity (50 U/kg), and a 150- μ g spray of Stimate was given the following day. The patient was also given Amicar (50 mg/kg) to take orally 4 times a day for 3-5 days. The patient healed without further incident.

Case 2

A 17-year-old boy presented to the oral and maxillofacial surgery service for removal of impacted third molar teeth 1, 17, and 32. His past medical history included cystic acne, mild depression, and hemophilia B that had been diagnosed at birth. The patient stated he could not take ibuprofen or aspirin but had no known true drug allergies. He was a nonsmoker. His current medications included isotretinoin, topiramate, fluoxetine, acetaminophen, and FIX infusions 2 times a week.

His brother was also diagnosed with hemophilia B. His mother and sister were both carriers of the hemophilia B gene. The patient's father had no signs or symptoms of the disease.

The patient was a well-developed, well-nourished teenager who was 73 inches tall and weighed 100 kg. He had bilaterally impacted third molar teeth and pericoronitis around mandibular molar teeth 17 and 32 (Fig 2). The patient was congenitally missing tooth 16.

After consultation with the patient's hematologist, the decision was made to perform the surgery in an operating room under general anesthesia. The patient was noted to have an FIX activity level of 8.6%. It was recommended that the FIX level be corrected to 100% prior to the invasive surgery, followed by a 50% correction 24 and 72 hours postoperatively. Additionally, it was recommended that the patient take aminocaproic acid (50 mg/kg) every 6 hours for 3-5 days. Extraction sockets were to be packed with gelatin foam and topical thrombin.

On the day of surgery, 10,000 U of recombinant FIX (BeneFix Coagulation Factor IX [Recombinant], Pfizer, Inc) was administered intravenously approximately 1 hour prior to the procedure. The surgery was accomplished without incident. The extraction sockets were packed with gelatin foam sponges covered with topical thrombin and closed with slowly resorbing sutures. Hemostasis was noted to be excellent, and the patient was discharged to home after recovery from anesthesia. An intravenous line was left in place to allow the patient to administer FIX infusions at home.

Postoperatively, the patient self-administered the 24- and 72-hour doses of 5000 U of recombinant FIX as directed and started taking the aminocaproic acid (50 mg/kg) every 6 hours by mouth. A telephone call to the patient on postoperative day 1 revealed no adverse issues related to hemostasis.

On postoperative day 4, the patient noted increased swelling on the mandibular right side of his face and came to the office for evaluation. A buccal space infection was diagnosed, and a conservative incision and drainage procedure was performed after consultation with the patient's hematologist. The patient was prescribed the antibiotic clindamycin, 300 mg every 6 hours for 1 week, and scheduled for follow-up in 2-3 days. He then self-administered an additional 5000 U of recombinant FIX at the direction of his hematologist. Follow-up examination revealed that the infection was resolved, and no further treatment was rendered.

Discussion

As stated previously, hemophilia is an X-linked recessive disorder caused by a deficiency in blood coagulation factors.¹ Hemophilia A, also called *true* or *classic hemophilia*, is characterized by a deficiency of FVIII, whereas hemophilia B, also known as *Christmas disease*, is caused by a deficiency of FIX.³ The incidence is estimated to be 1 in 5000 males for hemophilia A and 1 in 30,000 males for hemophilia B.² One-third of all hemophilia cases are the result of spontaneous mutations, and two-thirds are due to prior family history.⁴

Hemophilia is categorized by the degree of clinical factor activity. It is considered to be mild when plasma factor activity is 6%-40%, moderate if it is 1%-5%, and severe if it is less than 1% of normal.⁴ Although hemophilia A and B are considered clinically indistinguishable, recent evidence has shown that the bleeding phenotype of hemophilia B is less severe than that of hemophilia A.⁵ It has been suggested that patients with hemophilia B have lower bleeding frequencies and better long-term outcomes in terms of lower rates of total joint arthroplasty.⁵

Hemostasis is a process that arrests bleeding from a site of vascular injury. It is divided into primary and secondary hemostatic responses. Primary hemostasis occurs immediately after injury and results in the formation of a platelet plug.² Without the secondary hemostatic process, however, this plug may be rapidly sheared from the injured surface once the blood flow in the damaged vessel increases.² Secondary hemostasis involves a series of plasma proteins, which interact to form cross-linked fibrin, helping to stabilize the initial platelet plug.² Both FVIII and FIX circulate in the blood as inactive precursors that become activated at the time of injury as a part of the secondary hemostasis. The primary abnormality in patients with hemophilia is an inability to activate factor X, which is downstream from both FVIII and FIX, therefore inhibiting the generation of thrombin and fibrin to stabilize the initial platelet clot.²

Similar to the process of hemostasis, bleeding disorders are typically categorized into primary and secondary hemostatic defects.² Primary hemostatic disorders are related to disorders of platelets and von Willebrand factor. They present as symptoms of mucocutaneous bleeding, including epistaxis and petechiae, as well as easy bruising and bleeding after dental and surgical interventions.² Secondary hemostatic disorders, which are congenital or acquired deficiencies of clotting factors (such as hemophilia), present as delayed, deep bleeding into muscles and joints.²

In severe cases of hemophilia, recurrent bleeding into the joints results in joint deformity and may necessitate joint replacement.¹ In some mild cases, hemorrhage after dental extraction can lead to a diagnosis of hemophilia.² After an extraction in a hemophilic patient, the primary hemostatic process will work to form the platelet clot and bleeding will stop; however, oozing from the site may begin due to the body's inability to stabilize the clot without the appropriate secondary hemostasis and clotting factors.¹ As was witnessed in case 1, additional factor infusions may be needed if the clot is dislodged several days postoperatively, when factor levels have returned to presurgical levels and the patient has resumed a regular diet.

The primary treatment for patients with severe hemophilia is regular FVIII or FIX replacement therapy, also called *prophylactic therapy*, to prevent spontaneous bleeding into muscles and joints.³ Moderate and mild hemophilia are

characterized by bleeding on trauma, and therefore FVIII or FIX is given to these patients only in response to trauma or in anticipation of surgery.³

Dental management of a hemophilic patient requires collaboration among the dentist, oral surgeon, and hematologist. There is evidence to suggest that patients with hemophilia tend to delay dental treatment due to fear of bleeding from the dental procedure, necessitating more complex treatment when they finally present.¹ Both of the presented cases illustrate the challenges of managing such patients. What is routine postoperative care for a nonhemophilic patient can be complex in a patient with hemophilia. Both patients required follow-up with further factor infusions to manage dental postoperative complications involving prolonged bleeding following clot dislodgment or incision and drainage for infection. Dental practitioners should be aware that the management of these patients might require prophylactic factor replacement therapy, certain adjustments to treatment perioperatively, and close postoperative follow-up. For hemophilic patients requiring invasive surgical treatment, the use of clotting factor replacement therapy is recommended by the World Federation of Hemophilia.¹ Successful dental treatment protocols for hemophilic patients presenting for extractions include clotting factor replacement therapy, antifibrinolytic agents, and local hemostatic measures.

The decisions regarding clotting factor replacement therapy should be made in conjunction with the patient's hematologist. The main aim of providing what is known as *coagulant cover* is to raise plasma factor levels to normal in order to attain adequate hemostasis following dental extractions.¹ In general, for minor surgery, patients with hemophilia A and patients with hemophilia B require a plasma factor level of 50%-80% preoperatively and 30%-80% for 1-5 days postoperatively.⁴ Patients requiring general anesthetic must have factor replacement therapy in anticipation of endotracheal intubation, which can cause trauma-induced bleeding.¹ For major surgery, hemophilia A patients need a plasma factor level of 80%-100% preoperatively and 60%-80% for 1-3 days postoperatively.⁴ Hemophilia B patients require a plasma factor level of 60%-80% preoperatively and 40%-60% for 1-3 days postoperatively.⁴ Guidance from and collaboration with the patient's hematologist are essential to meeting the individual needs of the patient based on the severity of the hemophilia, the degree of trauma anticipated, and the dental treatment plan.

Antifibrinolytic agents are used in conjunction with clotting factor replacement therapy. These agents include lysine analogs such as tranexamic acid (Cyclokapron, Pfizer, Inc) and aminocaproic acid (Amicar). Both agents can be taken orally or intravenously.² These drugs prevent postoperative bleeding by inhibiting the activation of plasminogen to plasmin, which works to degrade fibrin clots. Thus, the administration of antifibrinolytic agents stabilizes clots.¹ The patients described in the present case reports were provided with aminocaproic acid to prevent postoperative bleeding. Stimate spray, which was used in the patient in case 1, is used to stop bleeding in patients with mild hemophilia A and mild to moderate von Willebrand disease. The active ingredient in Stimate, desmopressin acetate, acts in a way similar to the naturally occurring hormone vasopressin to trigger the release of von Willebrand factor and FVIII in the blood.¹

Local measures are an essential component of reducing postoperative bleeding in hemophilic patients presenting for extractions. In addition to pressure, vasoconstrictors in the anesthetic, and an atraumatic approach to surgery, other materials may be applied to the extraction site to arrest bleeding.⁴ Topical tranexamic acid can be placed in the extraction socket to aid in hemostasis.¹ Other hemostatic agents, such as Gelfoam (Pfizer, Inc) and INSTAT (Ethicon, Inc), which are bovine in origin and contain collagen, can be used as local measures.¹ Surgicel (Ethicon, Inc), which is synthetic and provides a framework for clot formation, aids with hemostasis but should be used with caution due to its acidic pH, which can irritate the extraction socket.¹

Aspirin and nonsteroidal anti-inflammatory drugs, which affect platelet function, should be avoided for pain management in patients with hemophilia.¹ Acetaminophen or combination drugs with codeine and acetaminophen may be a suitable alternative. It is important to manage the tissues atraumatically. The lingual tissues should be left undisturbed to prevent blood from tracking down the mediastinum.¹ It is vital to clean the wound well, and resorbable sutures should be used to avoid bleeding associated with removal.¹

Conclusion

Some patients with mild hemophilia may not be diagnosed until they have undergone invasive dental treatment. It is essential for clinicians to have the ability to identify patients with bleeding disorders and know how to best manage their care. Invasive

dental care procedures for patients with moderate to severe hemophilia ideally should be conducted in a specialized setting. In many cases, the patient must be hospitalized for surgical procedures. These decisions should be made by the dentist, in cooperation with the patient's hematologist, based on the planned dental procedure and the severity of the patient's disease. Preoperative consultation with the patient's medical provider and/or hematologist is essential, and further laboratory-based tests may be needed before dental treatment is rendered.

Author information

Dr Farrkh is a recent graduate, University of Colorado School of Dental Medicine, Aurora. Dr Garrison is in private practice, Aurora, Colorado. Dr Closmann is a former chief of oral and maxillofacial surgery, University of Colorado School of Dental Medicine.

References

1. Rafique S, Fiske J, Palmer G, Daly B. Special care dentistry, I: dental management of patients with inherited bleeding disorders. *Dent Update*. 2013;40(8):613-616, 619-622, 625-626 passim.
2. Kumar R, Carcao M. Inherited abnormalities of coagulation: hemophilia, von Willebrand disease, and beyond. *Pediatr Clin North Am*. 2013;60(6):1419-1441.
3. Dalati MH, Kudsi Z, Koussayer LT, Dalati MF, Mawla MF. Bleeding disorders seen in the dental practice. *Dent Update*. 2012;39(4):266-268, 270.
4. Peisker A, Raschke G, Schultze-Mosgau S. Management of dental extraction in patients with haemophilia A and B: a report of 58 extractions. *Med Oral Patol Oral Cir Bucal*. 2014; 19(1):e55-e60.
5. Franchini M. Current management of hemophilia B: recommendations, complications and emerging issues. *Expert Rev Hematol*. 2014;7(5):573-581.